

A very rare case of echinococcus granulosus arising in the ovary and the uterus

Angel Yordanov¹, Rosen Boncevi², Stoyan Kostov³, Yavor Kornovski³, Yonka Ivanova³, Stanislav Slavchev³, Venelina Todorova⁴, Konstantina Karakadieva¹, Lazar Tranchev⁵, Mariela Vasileva-Slaveva^{6,7}

¹Department of Gynaecological Oncology, Medical University Pleven, Pleven, Bulgaria

²Department of General and Clinical Pathology, University Hospital “D-r. Georgi Stranski”, Pleven, Bulgaria

³Department of Gynaecology, St. Anna University Hospital, Medical University-Varna “Prof. D-r. Paraskev Stoyanov”, Varna, Bulgaria

⁴Imaging department, University Hospital “D-r. Georgi Stranski”, Pleven, Bulgaria

⁵Medical University Pleven, Pleven, Bulgaria

⁶Department of Breast Surgery, Shterev Hospital, Sofia, Bulgaria

⁷Medical University Pleven, Research Institute, Pleven, Bulgaria

Abstract

Hydatidosis is a zoonosis caused by the larval form of a cestode of the species *Echinococcus granulosus*, the canine tapeworm. It can affect any organ of the human body except nails, hair, and cornea. It most often involves the liver, lungs, muscles, and bones. Involvement of organs in the small pelvis is extremely rare, mainly secondary to dissemination of hydatidosis from another organ, and the ovaries are most often involved, followed by the uterus. We present a 41-year-old Caucasian woman with complaints of mild pain, heaviness in the small pelvis, and a fibroid detected by ultrasound examination. She had reported for 2 previous operations for echinococcus cysts, and we found cystic formations in the liver and pelvis by computed tomography. It was decided that it is a recurrence of echinococcosis with a new cyst both in ovary and uterus. A hysterectomy with adnexectomy was performed, and one year later there is no evidence of recurrence of echinococcosis. In the presence of a formation in the small pelvis, one should always think about echinococcosis, especially if there is evidence of previous manifestations of the disease. Diagnosing this disease is extremely important for proper treatment. As rare as uterine involvement is, this possibility should not be overlooked.

Key words: *Echinococcus granulosus*, ovary, uterus, recurrence.

Introduction

Hydatidosis is a zoonosis caused by the larval form of a cestode of the species *Echinococcus granulosus*, the canine tapeworm. Humans can be an accidental intermediate host [1]. Hydatidosis is widespread throughout the world, especially the Mediterranean area, East Europe, South America, the Middle East, East Africa, and Australia [2].

Echinococcosis can affect any organ of the human body except nails, hair, and cornea [3]. It most often involves the liver (63%), lungs (25%), muscles (5%), and bones (5%) [4]. Involvement of organs in the small pelvis is extremely rare, at 0.2–2.25% of cases [5], mainly secondary to dissemination of hydatidosis from another organ [6–14].

In the small pelvis, the ovaries are most often involved (80%), followed by the uterus [5, 15].

We present a case of secondary echinococcosis in the pelvis, simultaneously involving the left ovary and the uterus.

Case report

We present a 41-year-old Caucasian woman, gravida 1, without accompanying diseases, who came to the clinic with complaints of mild pain, heaviness in

the small pelvis, and a fibroid detected by ultrasound examination. In amenorrhoea for 3 months. An intramural nodule measuring 39/45 mm and a septated cyst of the left ovary 44/40 mm were found from the ultrasound examination. From the anamnesis, she reported that in 1997 she was operated on urgently due to an acute abdomen, and it turned out that she had a ruptured echinococcal cyst of the liver. During the operation, 2 additional echinococcal cysts were found between the intestinal loops, which were removed together with the right adnexa.

In 2013, due to acute abdominal pain and a diagnosis of acute appendicitis, she was operated on again. One echinococcal cyst was found in the region of sigmoid epiploic appendages, reactively inflamed appendix, and myomatous enlarged uterus. The appendix and the echinococcus cyst were removed.

A computed tomography scan of the abdomen and pelvis was performed, and cystic formations were found in the liver and pelvis (Fig. 1).

As a result of the performed imaging studies, it was decided that it is about old single calcified echinococcal cysts in the liver and a suspected recurrence with a new cyst in a small pelvis – both in the ovary and uterus.

Corresponding author:

Angel Yordanov, Department of Gynaecological Oncology, Medical University Pleven, 5800 Pleven, Bulgaria, e-mail: angel.jordanov@gmail.com

Submitted: 28.12.2022

Accepted: 18.04.2023

Echinococcal IgG antibodies were tested with ELISA–0.5 (negative result). The results of the full blood count and biochemistry were normal.

An abdominal total hysterectomy with left adnexectomy was performed (Fig. 2).

The histological result was as follows: basal endometrium and myometrium with endometriosis, leiomyoma nodes with secondary changes, 2 echinococcal cysts PAS (+), ovarian parenchyma with white bodies, fibrous cyst wall with calcium deposits, lined with chitin membrane PAS (+) (Fig. 3).

The patient was discharged on the 4th postoperative day without complications. One year later, there is no evidence of recurrence of echinococcosis.

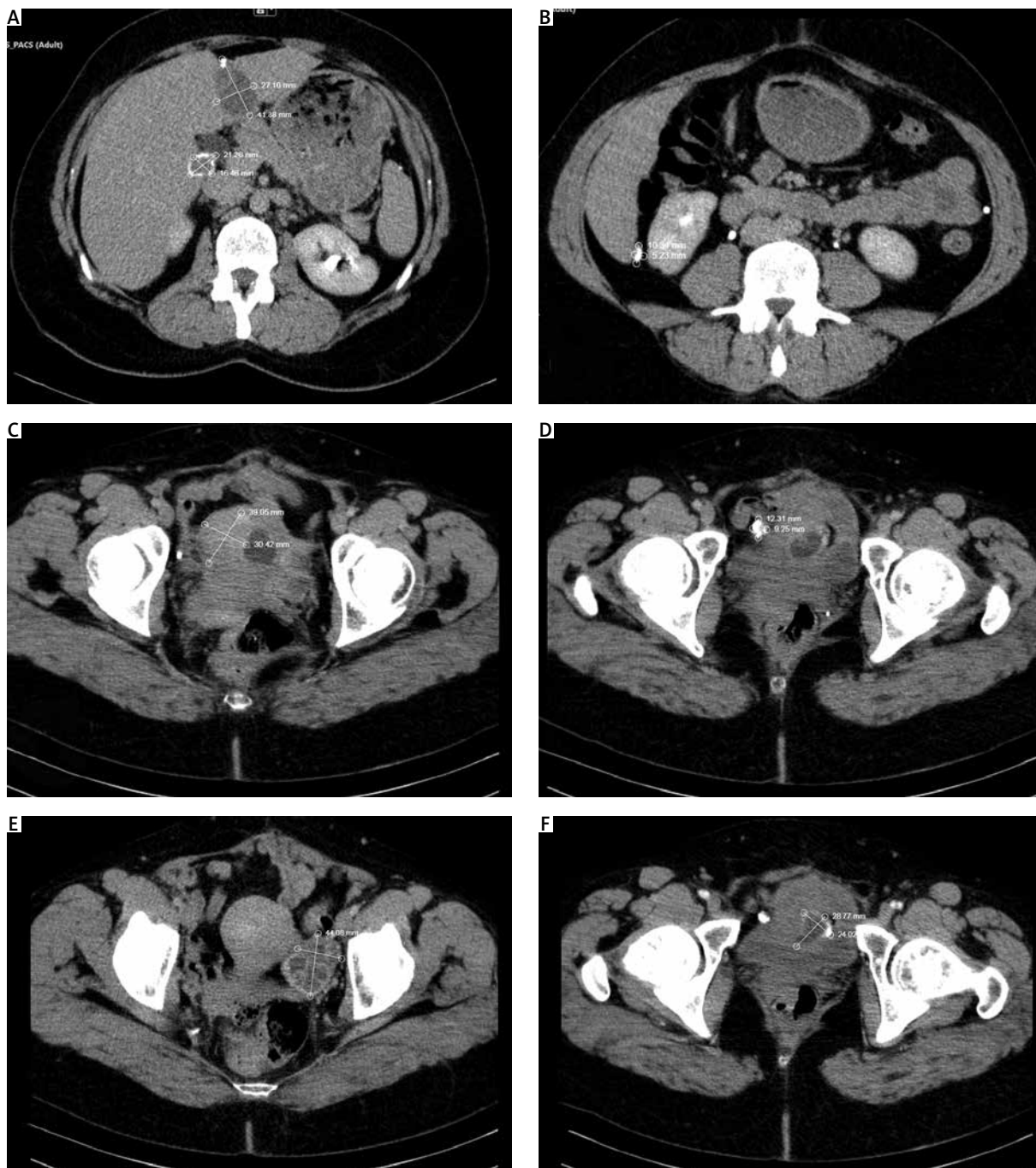


Fig. 1. Computed tomography scan findings: old hepatic echinococcal cysts – at the border of the left/right liver lobe a separated cystic lesion, in places with calcium inclusions in the wall 42/27 mm and in the right lobe paracaval devitalized echinococcal cyst 21/16 mm (A), calcifications subcapsular 10/5 mm (B), intramural fibroid node 39/30 mm (C), lesion with calcium density in the right parauterine 12/9 mm (D), in the area of the left ovary, a hyperdense, separated lesion with calcium deposits 44/31/41 mm (E), cyst formation in the uterine wall 29/24 mm (F)

Discussion

Each year, between 2 and 3 million cases of human echinococcosis are observed worldwide [16]. Endemic areas are the Middle East, the southern part of South America, Iceland, Australia, New Zealand, southern parts of Africa, Central Asia, and China [3]. *Echinococcus granulosus* usually affects a single organ and presents as a slowly growing (0.5–3 cm per year), noninvasive, unilocular cystic lesion [3]. In 10–15% of cases it affects 2 organs [17]. Pelvic involvement is rare (0.3–0.9%), with 80% involving the genitalia, and the ovaries being more commonly involved than the uterus [3]. This usually occurs secondarily to intra-abdominal rupture of a hydatid cyst of the liver, although cases of primary uterine involvement have also been described [18].

The clinical picture of pelvic echinococcosis is non-specific: abdominal swelling, abdominal pain, menstrual abnormalities, infertility, and urinary disturbances [9]. Ovarian or uterine echinococcosis can mimic polycystic ovaries or malignancy [10, 11], multicystic ovarian tumour, haemorrhagic ovarian cyst, endometrioma, cystadenoma, leiomyoma, etc. [19, 20].

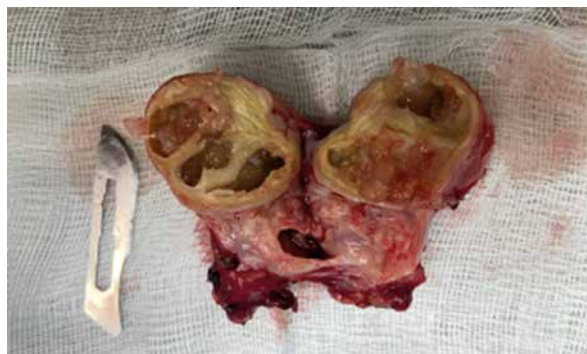

Fig. 2. Macroscopic view of the left ovary

The diagnosis is supported by ultrasound examination or computed tomography (CT) scan because the images do not have specific characteristics [11]. The anamnesis is of utmost importance because it can lead the doctor to think about this disease. Early diagnosis is very important because it allows the surgeon to prepare for operative treatment, which is the gold standard of treatment. The surgeon must avoid intra-operative iatrogenic rupture, which can lead to anaphylactic shock, and when necessary, pre-administer

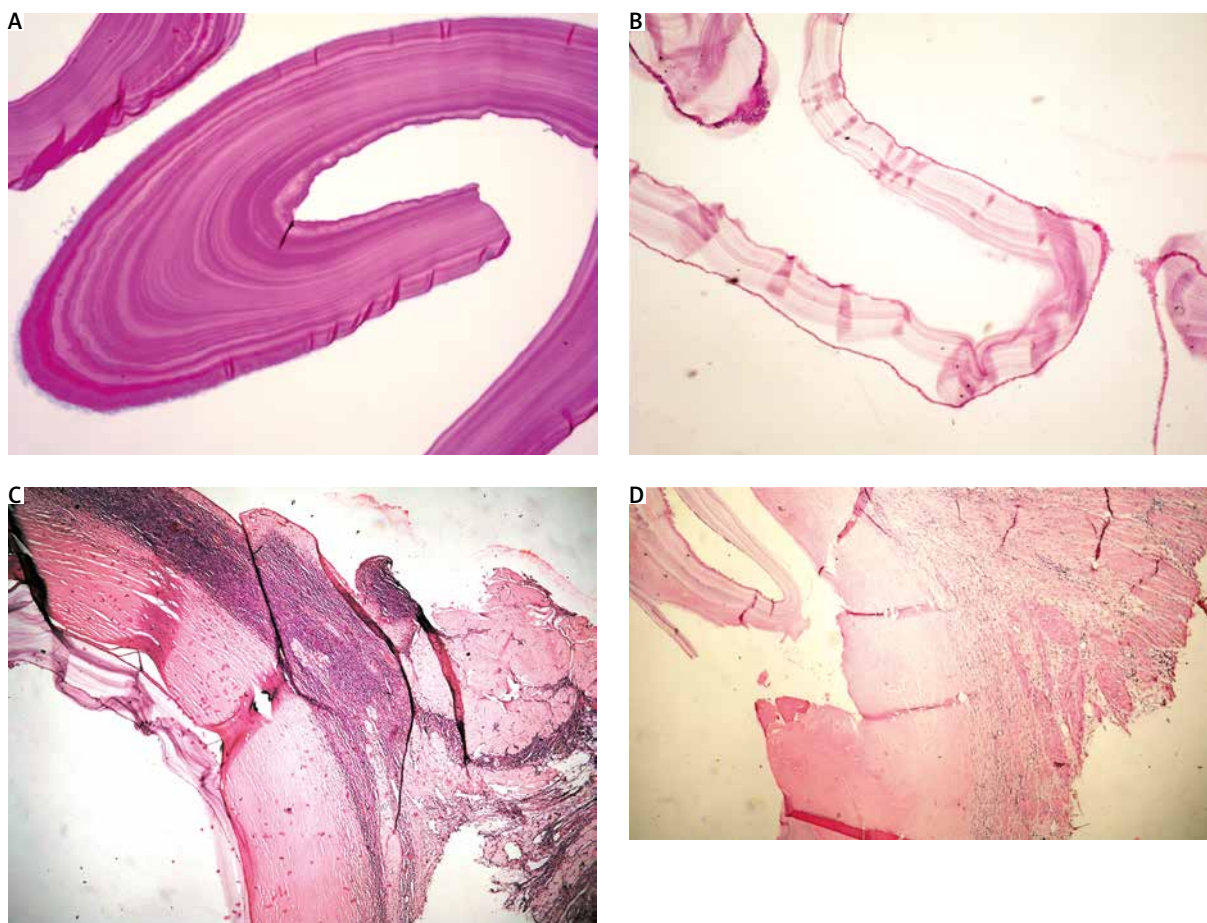


Fig. 3. Histological findings: ovarian parenchyma with white bodies, fibrous cyst wall with adjacent chitinous membrane – 40×, H and E (A), chitin membrane with germ layer – 100×, H and E (B), chitin membrane with germ layer – 100×, PAS (C), myometrium with fibrous cyst wall with adjacent chitinous membrane with germ layer – 40×, H and E (D)

albendazole-based therapy to reduce the risk of spread, which can lead to relapses [12]. Surgical treatment can be radical (removal of the cyst with the affected organ) or conservative (removal of the cyst only) [2]. If impossible, the cyst can be aspirated and marsupialized [4].

In our case, the diagnosis was made after the ultrasound examination, due to the previous history of 2 surgical interventions in the abdomen for echinococcosis.

Our patient presented with nonspecific complaints of pain and heaviness, but despite this, a decision was made to perform a hysterectomy with left adnexectomy due to the presence of a cystic formation in the uterus, which was detected on CT. In this case, it is a case of secondary echinococcosis (both in the ovary and uterus), which occurred most likely as a result of a previous rupture of a liver cyst.

As far as we know, this is the second case described in the literature with echinococcosis being found simultaneously in the uterus and ovary. The first case was from 1969 and was described in Bulgaria [21].

Only a few cases with primary fallopian tube involvement are reported in the literature – less than 30 [22]. Usually, they are diagnosed during surgery or as paraovarian cysts [23, 24].

The involvement of the uterus is another rare location of echinococcosis, and it can occur primarily or secondarily [3]. It was reported for the first time by Guedana in 1990 [25], and there are no specific diagnostic symptoms.

From the female reproductive organs, hydatidosis occurs most often in the ovaries, and it can be a primary or secondary disease [2].

Conclusions

In patients with a positive history of previous echinococcosis, especially in endemic areas, echinococcosis should be considered as a possible cause of pelvic mass. Diagnosing this disease is extremely important for proper treatment. As rare as uterine involvement is, this possibility should not be overlooked.

Disclosure

The authors report no conflict of interest.

Informed consent was signed by patient.

The authors declare that all related data are available concerning researchers via the corresponding author's email.

References

- Bourée P. Hydatidosis: dynamics of transmission. *World J Surg* 2001; 25: 4-9.
- Aksu MF, Budak E, Ince U, Aksu C. Hydatid cyst of the ovary. *Arch Gynecol Obstet* 1997; 261: 51-53.
- Ennaceur F, Toumi D, Jaouad F, et al. Primary echinococcus hydatid cyst of the uterus: an unusual location. *Case Rep Surg* 2021; 2021: 9977326.
- Cattorini L, Trastulli S, Milani D, et al. Ovarian hydatid cyst: a case report. *Int J Surg Case Rep* 2011; 2: 100-102.
- Diaz-Recasens J, Garcia-Enguidanos A, Munoz I, Sainz de la Cuesta R. Ultrasonographic appearance of an echinococcus ovarian cyst. *Obstet Gynecol* 1998; 91: 841-842.
- Uchikova E, Pehlivanov B, Uchikov A, Shipkov C, Poriazova E. A primary ovarian hydatid cyst. *Aust N Z J Obstet Gynaecol* 2009; 49: 441-442.
- Konar K, Ghosh S, Konar S, Bhattacharya S, Sarkar S. Bilateral ovarian hydatid disease – an unusual case. *Indian J Pathol Microbiol* 2001; 44: 495-496.
- Adewunmi OA, Basilingappa HM. Primary ovarian hydatid disease in the Kingdom of Saudi Arabia. *Saudi Med J* 2004; 25: 1697-1700.
- Dede S, Dede H, Caliskan E, Demir B. Recurrent pelvic hydatid cyst obstructing labor, with a concomitant hepatic primary. A case report. *J Reprod Med* 2002; 47:164-166.
- Pekindil G, Tenekeci N. Solid-appearing pelvic hydatid cyst: transabdominal and transvaginal sonographic diagnosis. *Ultrasound Obstet Gynecol* 1997; 9: 289-291.
- Aysun A, Petek BK, Mehmet AY, Omer Yalcin. Huge solitary primary pelvic hydatid cyst presenting as an ovarian malignancy: case report. *J Turkish German Gynecol Assoc* 2009; 10: 181-183.
- Arif SH, Shams-UI-Bari, Wani NA, et al. Albendazole as adjuvant to the standard surgical management of hydatid cyst of liver. *Int J Surg* 2008; 6: 448-451.
- Hamamci EO, Besim H, Korkmaz A. Unusual locations of hydatid disease and surgical approach. *ANZ J Surg* 2004; 74: 356-360.
- Zia S, Enam A, Salahuddin I, Khan A. Role of irrigation with hypertonic saline for a recurrent skull base hydatid cyst: case report and review of the literature. *Ear Nose Throat J* 2010; 89: E22-6.
- Baba L, Chaieb H, Keskes J. Profil epidemiologique d l'hydatidose pelvienne. *J Gynecol Obstet Reprod (Paris)* 1991; 20: 657-660.
- Peker K, Uluğ R, Naykı ÜA, et al. Primary uterine hydatid cyst: a case report. *Türkiye Parazitoloj Derg* 2013; 37: 302-304.
- Brunetti E, Kern P, Vuitton DA. Expert consensus for the diagnosis and treatment of cystic and alveolar echinococcosis in humans. *Acta Trop* 2010; 114: 1-16.
- Bouihji J, Moustaid H, Amrani BE, Mimouni A. Kyste hydatique pelvien primitif: à propos d'un cas [Primary pelvic hydatid cyst: about a case]. *Pan Afr Med J* 2016; 25: 239.
- Görgen H, Api M, Cetin A. Primary adnexial hydatid cyst mimicking ovarian tumor. *J Turk Ger Gynecol Assoc* 2009; 10: 232-234.
- Koç N. Primary hydatid cyst mimicking uterine leiomyoma. *Türkiye Parazitoloj Derg* 2017; 41: 57-59.
- Mirkov K. Slučaj s ekhinokok na matkata i jaichnika [A case of echinococcosis of the uterus and ovary]. *Akush Ginekoloj (Sofia)* 1969; 8: 184-187.
- Musa DH, Mohammed AA. Hydatid cyst of the fallopian tube; case report with literature review. *Int J Surg Case Rep* 2020; 66: 101-103.
- Nazari Z, Torabizadeh J. Primary hydatid cyst of the fallopian tube: a case report. *Caspian J Intern Med* 2014; 5: 179-181.
- Jafarian A, Fakhari N, Parsaei R. Hydatid cyst of fallopian tube. *Ann Med Health Sci Res* 2014; 4: S324-S325.
- Guedana F, Chemmen Lebbene L, Lebbi I, Koubaa A, Benzined T, Benjilani S. Hydatidose intra-utérine. A propos d'un cas [Intrauterine hydatidosis. A case report]. *J Gynecol Obstet Biol Reprod (Paris)* 1990; 19: 725-727.